

Detection and Localization of Anti and Pro-apoptotic mRNA Genes in Human Colorectal Cancer Using *in situ* RT-PCR

¹Mohd. Nazil Salleh, ²Boo Siaw Shi, ¹Wan Khairuzzaman Wan Ramli,
¹Azlina Zahari, ³Norashikin Shamsudin and ⁴Thuaibah Hashim

¹Department of Medical Laboratory Technology, Faculty of Biomedical and Health Sciences, University Industry Selangor, Section 7, 40000 Shah Alam Selangor, Selangor, Malaysia

²Department of Biomedical Sciences, Faculty of Medicine and Health Sciences,

³Department of Medicine, Faculty of Medicine and Health Sciences, University Putra Malaysia, 43400 UPM Serdang, Malaysia

⁴Department of Histopathology, No. 3410, Jalan Teknokrat 3, Cyber 4, 63000 Cyberjaya, Cyberjaya University College of Medical Sciences, Malaysia

Abstract: Problem statement: Recent studies using conventional Polymerase Chain Reaction have shown that anti-apoptotic (Cyclooxygenase-2, COX-2 and Nuclear Factor- κ B, NF- κ B) and pro-apoptotic mRNA (Bax and Bad) are involved in the tumorigenesis of colorectal cancer. The aim of this study was to localize the expression of anti and pro-apoptotic mRNA genes using Reverse Transcription *in situ* Polymerase Chain Reaction (RT *in situ* PCR) and immunodetection technique in the early stage of human colorectal adenocarcinoma. **Approach:** Reverse Transcription *in situ* Polymerase Chain Reaction (RT *in situ* PCR) and immunodetection technique was applied throughout of this studies. 20 paraffin-embedded tissue blocks of human colorectal adenocarcinoma samples was used compared to controls. **Results:** Morphologically, the glands and crypts were well-differentiated, enlarged and irregular with active secretion of mucin. COX-2, NF- κ B, Bax and Bad mRNA were expressed in both normal and human colorectal cancer tissues. All mRNA genes were expressed in the cytoplasm and nuclei. However, COX-2 and NF- κ B mRNA genes were highly expressed with higher intensity of brown staining compared to Bax and Bad at tubular epithelium cells. **Conclusion:** This study demonstrated that by using RT *in situ* PCR, COX-2 and NF- κ B mRNA genes were shown to be involved in the development of human colorectal cancer.

Key words: Cyclooxygenase-2 (COX-2), Nuclear Factor- κ B (NF- κ B), heterodimeric partner for Bcl-XL and Bcl-2 (Bad), bcl-2 associated X protein (Bax), *in situ* Reverse Transcription Polymerase Chain Reaction (*in situ* RT-PCR)

INTRODUCTION

Colorectal cancer is the second leading cause of death in western countries (Rainford, 2000; Ruegg *et al.*, 2004; Midgley and Kerr, 1999). According to Malaysia Ministry of Health, Human Colorectal Cancer (HCC) ranked third among cancer cases reported, accounting for 7.8 and 5.6% in males and females respectively (Lim, 2006). Unfortunately, the peak incidence for colorectal cancer is 60-70 years of age and highest among Chinese (King and Robins, 2006).

Colorectal cancer, including the rectum, is the host to more primary neoplasms than any other organ in the

body. About 90% of the colon cancer characterized as adenocarcinoma whereas the other 10% is mucinous adenocarcinoma (King and Robins, 2006). Approximately 98% of all cancers in the large intestine are adenocarcinomas (Robbins, 2004). This disease is curable in early stages (Tsuji *et al.*, 1997). Adenocarcinoma is malignant epithelial tumor arising from glandular structures, which are constituent parts of most organs of the body and tumors showing a glandular growth pattern (Wiesner *et al.*, 2003).

In this study, an RT *in situ* PCR method was conducted to investigate the expression of anti-apoptotic (COX-2 and NF- κ B) and pro-apoptotic (Bax

Corresponding Author: Mohd. Nazil Salleh, Department of Medical Laboratory Technology, Faculty of Biomedical and Health Sciences, University Industry Selangor, Section 7, 40000 Shah Alam Selangor, Selangor, Malaysia Tel: 603-5522 3421 Fax: 603-5522 3523

and Bad) mRNA in human colorectal adenocarcinoma. These four genes are believed to be involved closely in the tumorigenesis in human colorectal adenocarcinoma. COX-2 mRNA expression detected at higher levels than in normal colorectal mucosa (Hasegawa *et al.*, 2001). Nuclear Factor- κ B (NF- κ B) is a transcription factor which plays an important role in inducible expression of diverse cellular genes, mostly involved in host defense such as genes for various cytokines, cell-surface receptors (Fujimoto *et al.*, 1995) play and plays a role in the pathogenesis in intestinal mucosa. Native Bax become apoptotic even without external stimuli and without blocking the antiapoptotic activity (Ishibashi *et al.*, 1998). Bad gene, the Bcl-XL/Bcl-2-associated death promoter, has been shown to be mutated occasionally in colon cancers and that somatic mutation of Bad may contribute to the development of colon cancers (Lee *et al.*, 2004).

The present study was using RT *in situ* PCR technique which allows detection of very low copy of mRNA in cellular level with rapid and sensitively method to investigate a specific mRNA gene was applied. In conclusion, our findings had shown that, the expression of COX-2, NF- κ B, bad and bax mRNA was detected in early stage development of colorectal adenocarcinoma/tumorigenesis.

MATERIALS AND METHODS

Preparation of tissue sections: Human colon and rectal cancer samples (n = 20) obtained underwent normal histological process. The tissues are sectioned at the thickness of 4 μ m and placed on microscopic glass slides for H&E staining for histopathological examination and topological orientation whilst tissue sections fished on silane-coated slides were preceded with RT *in situ* PCR. This project was approved by the ethical committee of Faculty of Medicine and Health Sciences, Malaysia.

Processing and pre-treatment of tissue sections: Tissue sections were incubated for 2 h at 70°C in incubator to ensure tissue adhere to the slides. Tissue sections were dipped into xylene and ethanol with decreasing concentration. The slides were then washed with DEPC-treated water until clean and dried for 10 min at rt. Sections were treated with 7.5 μ g mL⁻¹ Proteinase K for 45 min at 37°C on heat block. Tissue digestion conditions were standardized by optimizing in graded concentration of Proteinase K to an optimal time. These steps are necessary in order to preserve morphology and to facilitate the access of the RT-PCR mixture to the nucleic acid sequences. PBS was used to wash off Proteinase K and its digestion was inactivated at 95°C for 1 min on heat block. The slides were then

rinsed firstly in PBS, followed by in DEPC-treated water and then air-dried. The genomic DNA in each section was digested with 50 μ L RNase-free DNase I (20 U) overnight at 37°C in humid chamber to avoid non-specific amplification of the DNA by the Tfl DNA polymerase. Optimization was done by testing different concentration of DNase I and different time exposure. After DNase treatment, the slides were thoroughly washed with DEPC water for 1 min, followed by 100% ETOH for 1 min and air-dried.

Labeling of probes: Six groups of 20-mer oligonucleotide probes (Table 1) complementary to p53, p21 and bax mRNA were synthesized. The sequences were labeled by tailing the 3' end using digoxigenin-11-dUTP. The primers were designed online using Primer3 (www.primer3.com).

One-step RT *in situ* PCR assay: A modified one-step RT *in situ* PCR approach was performed using the techniques of Nuovo (1996). Tissue section was outlined with *in situ* Frame. Each slide was loaded with 50 μ L of a RT-PCR mixture which consists of 30.0 μ L Nuclease-free water, 10.0 μ L AMV/Tfl 5X reaction buffer, 2.0 μ L of 25 mm MgSO₄, 2.0 μ L of 5 10 mm dNTP, 1.0 μ L for each forward and reverse primer (p53, p21 and Bax), 1.5 μ L 2% BSA, 0.5 μ L digoxigenin-11-dUTP, 1.0 μ L AMV Reverse Transcriptase (5 μ μ L⁻¹) and 1.0 μ L of Tfl DNA polymerase (5 μ μ L⁻¹). An incubation chamber was made with an *in situ* cover slip and the sections stabilized by an *in situ* adapter in Eppendorf Mastercycler (Germany) with *in situ* block. Reverse transcription was performed on 45°C for 45 min. Subsequently the incubation was followed by hot start for initial denaturation, which was carried out at 94°C for 2 minutes. Denaturation steps was performed at 94°C for 45 sec, annealing at 53°C for 40 sec, elongation at 68°C for 1 min and repeated for 34 cycles followed by final elongation at 68°C for 4 min and finally cooled at 4°C for 10 min.

Table 1: Eight groups of 20-mer oligonucleotide probes complementary to Bax, Bad, COX-2 and NF- κ B mRNA were synthesized. The primers were designed online by using Primer3 (www.primer3.com)

Primers	Sequences	Length (bps)
Bax	Sense 5'-TTTGCTTCAGGGTTTCATCC-3'	246
	Antisense 5'-CAGTTGAAGTTGCCGTCAGA-3'	
Bad	Sense 5'-CGGAGGATGAGTGACGAGTT-3'	180
	Antisense 5'-GATGTGGAGCGAAGGTCACT-3'	
COX-2	Sense 5'-TGACATCTACGGTTTGCTG-3'	158
	Antisense 5'-TGCTTGCTGGAACAACCTGC-3'	
NF- κ B	Sense 5'-GCGAGAGGACACAGATACC-3'	250
	Antisense 5'-CTGATAGCTGCTCCAGTCC-3'	

COX-2: Cyclooxygenase-2; NF- κ B: Nuclear Factor- κ B; bps: Base pairs

Immunodetection of PCR products: After RT-PCR process, *in situ* Frame was gently removed and the slides were flooded with PBS for 5 min to saturate the non-specific sites and then washed in PBS twice time properly. Endogenous peroxidase in the specimen was blocked by incubating in 6% hydrogen peroxide in absolute methanol for 30 min in dark humid chamber and followed by rinsing with PBS in Tween 20 for 2 min. The slides were then treated with BSA for 15 min in humid chamber. The slides were flooded with PBS in Tween 20 for 2 min and then washed slides with PBS in Tween 20 for 10 min. To visualize the PCR signal, digoxigenin-labeled PCR products were detected by incubating with $50 \mu\text{L}^{-1}$ anti-digoxigenin-gold 150 U m L^{-1} diluted in 1:30 with BSA in PBS ($1 \text{ mg BSA } 1 \text{ mL}^{-1}$ PBS) pH 7.5 for 30 min at rt in humid chamber. The slides will be washed in 0.05% Tween 20 in PBS and then in deionised water. The sections were developed for 12 min at rt with $100 \mu\text{L}$ DAB chromogen in dark until brown color development was visible. The slides were flooded with 0.05% Tween 20 in PBS and were then rinsed n distilled water. The slides were then counterstained with Hematoxylin and continued with dehydration procedure by dipping into ethanol with increasing concentration and xylene. The slides were mounted with DPX and covered with coverslips. The slides were observed under light microscope and analysis of image will be carried out.

RESULTS

Histological analysis: Colon tissue sections are stained by using H&E staining to observe the morphological changes of these sections. In Plate 1A and 1B, these sections showed that well-differentiated, hyperplastic and irregular glands are crowded within mucosal layer. Some glands are enlarged (Plate 1A) and some crypts are distorted and some epithelial lining of the glands have lost its normal architecture (Plate 1B). The nuclei are stratified but still remain in the basal half of the cells (Plate 1C). In, addition most of the glands showed active mucin secretion activity (Plate 1C and D). There is no invasion observed in these cases. Amorphous debris was observed in the lumen of the glands as shown in Plate 1A and C.

Reverse Transcription *in situ* Polymerase Chain Reaction (RT *in situ* PCR):

Optimization of positive and negative control: In our study, strong brown staining was observed in most cells with positive control and no brown staining was observed in the negative controls were prerequisite for success with RT *in situ* PCR. In positive control, the tissue was pretreated with Proteinase K without DNase I digestion. Plate 2A showed a very strong intense brown

staining demonstrates that proteinase K digestion was effective and subsequent PCR steps were successful. As for negative control, tissues were pretreated with Proteinase K and DNase I digestion but with omission of antidigoxigenin-gold (Plate 2B), DNA polymerase (Plate 2C), digoxigenin-11-dUTP (Plate 2D) and primer (Plate 2E). All the negative controls showed no brown staining which indicate that the products detected was indeed cDNA and not priming from contaminating genomic DNA.

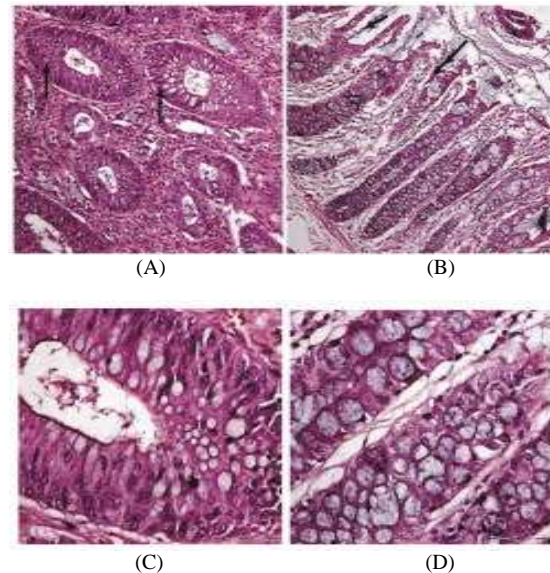


Plate 1: These are human colon adenocarcinoma sections stain with H&E staining. (A) Well differentiated adenocarcinoma of colon. This section shows crowded neoplastic and enlarged glands. In between the glands, there is infiltration of inflammatory cells. There is amorphous debris (arrow) in the lumen of the neoplastic glands at magnification 100X. (B) Well differentiated glands show active mucin secretion as there is increase in number of goblet cells. The epithelial lining of the glands seem to be hyperplastic. Some glands have lost their normal architecture (arrow). The lamina propria is infiltrated with inflammatory cells at magnification 100X. (C) The enlarged nuclei are stratified but mostly remain in the basal half of the cells. Amorphous debris can be observed in the lumen of the glands (arrow) at magnification 400X. (D) The glands are full of goblet cells. In the lamina propria, the inflammatory cells (basophilic cells) show scanty cytoplasm (arrow) at magnification 400X

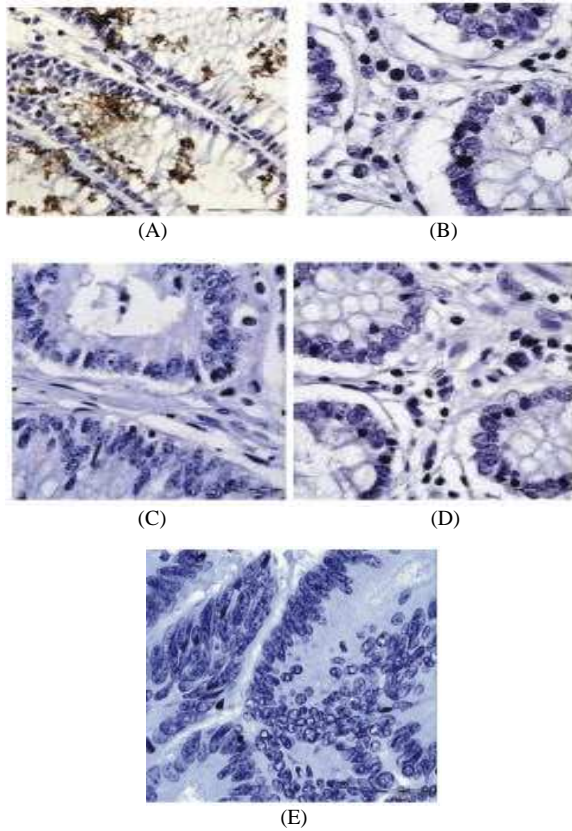


Plate 2: These are controls done by using RT *in situ* PCR technique at magnification 400X. (A) This is the positive control with omission of DNase treatment done on human rectal adenocarcinoma section. The intensity of nuclear very strongly intense. (B) The negative control with omission of anti-digoxigenin-gold. No brown staining is observed. (C) The negative control with omission of DNA polymerase. No brown staining is observed. (D) The negative control with omission of digoxigenin-11-dUTP. No brown staining is observed. (E) The negative control with omission of primer. No brown staining is observed

Expression of Cox-2, NF-κB, Bax and Bad mRNA:

In normal colon tissue, the glands were lined with unbranched simple tubular epithelial cells at magnification of 400X. All four genes, Bax, Bad, COX-2 and NF-κB were found to be expressed in the normal colon tissues. Bax gene was found in cytoplasm and nuclei of gland cells (Plate 3A). In Plate 3B, brown staining was observed the mucin producing glands but not in the gland without mucin secretion activity. Bad gene was found in both cytoplasm and nuclei.

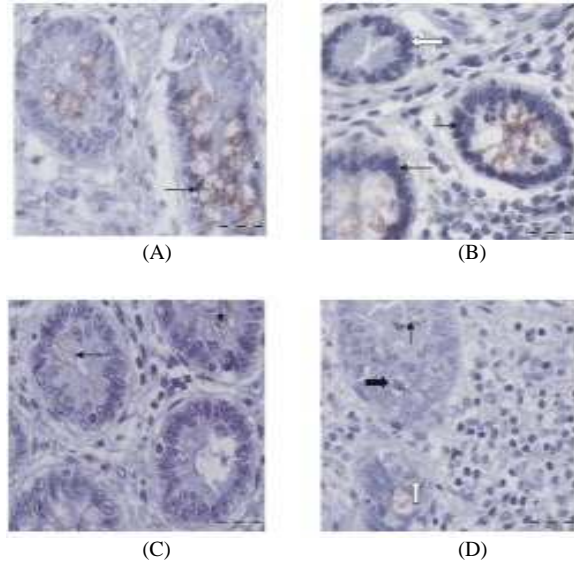


Plate 3: RT *in situ* PCR detection of anti- and pro-apoptotic mRNA in normal human colon sections at magnification 400X. (A) Detection of Bax mRNA. The glands are lined by unbranched simple tubular epithelial cells. Brown staining can be observed in the cytoplasm and nuclei (arrow) of the glands. (B) Detection of Bad mRNA. Brown staining is observed in the mucin producing glands (black arrow) but not in the gland which do not have mucin secretion activity (white arrow). Brown staining can be observed in the cytoplasm and nuclei (arrow). (C) Detection of COX-2 mRNA. Brown staining can be seen in some of the columnar epithelial cells of the glands (arrow). (D) Detection of NF-κB mRNA. Brown staining can be detected in the cytoplasm (arrow) as well as in the nucleus (close arrow) with prominent nucleolus (white arrow)

COX-2 gene was found to be expressed in the columnar epithelial cells of the glands (Plate 3C). While NF-κB gene was observed in cytoplasm and nucleus in normal colon tissue (Plate 3D).

In colon adenocarcinoma section, some glands showed active mucin secretion activity (Plate 4A-D). Bax gene was found in cytoplasm and nuclei of the glands as shown in Plate 4A. Bad gene was also found in both 7 cytoplasm and nuclei as shown in Plate 4B. In Plate 4C, COX-2 gene was found to be expressed in both cytoplasm and nuclei in human colon adenocarcinoma tissue. In Plate 4D, NF-κB gene was observed to be expressed in both nuclei and cytoplasm of the glands in human colon adenocarcinoma tissue.

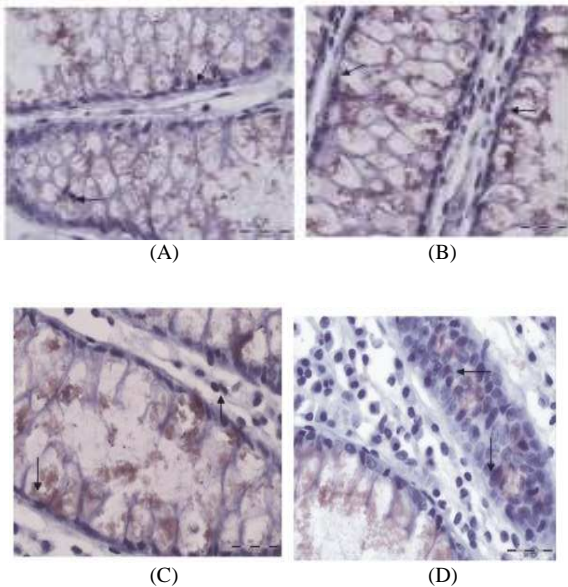


Plate 4: RT *in situ* PCR detection of anti- and pro-apoptotic mRNA in human colon adenocarcinoma sections at magnification 400X. (A) Detection of Bax mRNA. The glands show active mucin secretion activity. Brown staining can be detected in the cytoplasm and nuclei of the glands (arrow). (B) Detection of Bad mRNA. The glands show active mucin secretion activity. Brown staining can be detected in the cytoplasm and nuclei of the glands (arrow). (C) Detection of COX-2 mRNA. The glands show active mucin secretion activity. Brown staining can be detected in the cytoplasm and nuclei of the glands (arrow). (D) Detection of NF-κB mRNA. The glands show active mucin secretion activity. Brown staining can be detected in the cytoplasm and nuclei of the glands (arrow)

In rectal adenocarcinoma tissue at magnification of 400X, the nuclei of the cells appear to be enlarged with prominent nucleoli, hyperchromatic (Plate 5A-C), some are in pencil shape (Plate 5A) and some are rounded (Plate 5B). In Plate 5A, the Bax mRNA was found to be expressed in cytoplasm as well as in the nucleus. Brown staining can be observed in cytoplasm and nucleus for detection of Bad mRNA as shown in Plate 5B. Meanwhile, COX-2 mRNA can be observed in the cytoplasm and nucleus (Plate 5C). NF-κB was found to be expressed in cytoplasm and nucleus (Plate 5D).

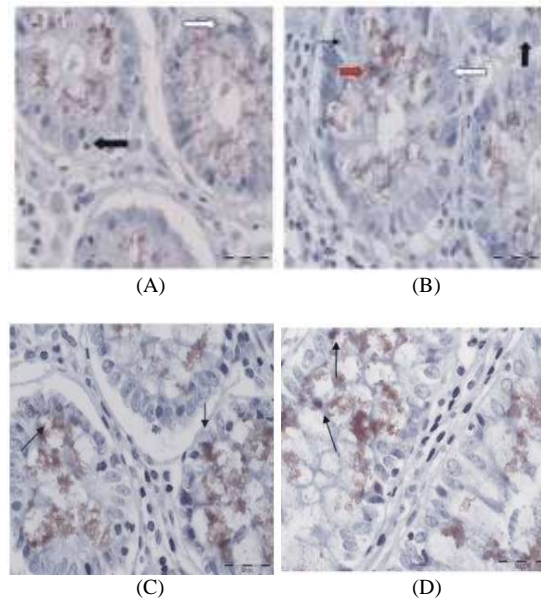


Plate 5: RT *in situ* PCR detection of anti- and pro-apoptotic mRNA in human rectal adenocarcinoma sections at magnification 400X. (A) Detection of Bax mRNA. The nuclei appear to be enlarged with prominent nucleoli (close arrow), hyperchromatic and some are in. (B) Detection of Bad mRNA. Nuclei of the glands are irregular in shape, some are rounded (arrow) and some are elongated (open arrow). Nuclei are hyperchromatic with prominent nuclei (close arrow). Brown staining can be observed in the cytoplasm as well as the nucleus (red arrow) of the glands. (C) Detection of COX-2 mRNA. The nuclei are irregular, hyperchromatic and vascular with prominent nucleoli. Brown staining can be observed in the cytoplasm as well as in the nucleus (close arrow). (D) Detection of NF-κB mRNA. Brown staining can be visible in the cytoplasm as well as in the nucleus (arrow). Some nuclei are enlarged

In normal colon tissue, brown staining was observed in glandular cells for the detection of Bax and Bad (Plate 3A and 3B) with higher intensity compared to COX-2 and NF-κB (Plate 3C and 3D) mRNA respectively. In all cases, brown staining was observed for the detection of Bax, Bad, COX-2 and NF-κB mRNA genes in nuclei and cytoplasm of epithelial cells of the glands (Plate 4A, 4B, 4C and 4D). However, intensity of brown staining for COX-2 and NF-κB (Plate 4C and 4D) mRNA was observed to be higher

compared to Bax and Bad (Plate 4A and 4B) in colon adenocarcinoma tissue.

DISCUSSION

Colorectal cancer has long been associated with disturbances in apoptosis regulation. The rate of tumor growth depends on the balance between proliferation and apoptosis at all stages of carcinogenesis (Samojednya *et al.*, 2004). Epidemiological studies have indicated a negative relationship between colon cancer risk and the use of Nonsteroidal Anti-Inflammatory agents (NSAIDs) (Williams *et al.*, 1997). Contrastingly, Hanif *et al.* (1996) and Giovannucci *et al.* (1994) showed that NSAIDs inhibit the proliferation rate, alter the cell cycle distribution and induce apoptosis in colon cancer cell lines.

In our present study, anti-apoptotic (COX-2 and NF- κ B) and pro-apoptotic (Bax and Bad) mRNA are expressed in the human colon and rectal adenocarcinoma tissue by using RT *in situ* PCR. COX-2 and NF- κ B are highly expressed compared to Bax and Bad mRNA in the human colon and rectal adenocarcinoma samples. Colon tissue sections are stained by using H&E staining to observe the morphological changes which show these well-differentiated glands with mucin secretion activity are enlarged and some are irregular in shape. Some crypts are distorted. The nuclei are irregular, enlarged, hyperchromatic and with prominent nucleoli. The nuclei are striated but still remain in the basal half of the cells. No invasion was observed.

In the present study, brown staining observed in all the colorectal adenocarcinoma cases which showed that Bax, Bad, COX-2 and NF- κ B mRNA are expressed in both normal and cancerous cells. These genes were found to be expressed in nuclei and cytoplasm of epithelial cells of the glands.

COX-2 and NF- κ B mRNA can be observed to be expressed in all the glands in the cancerous tissues. In normal tissue, Bax and Bad mRNA are expressed in the glands and crypts near the superficial epithelial lining with the intensity of brown staining stronger compared to COX-2 and NF- κ B mRNA. In all colorectal tissues, COX-2 and NF- κ B mRNA showed stronger intensity of brown staining than Bax and Bad mRNA. Thereby, our finding suggesting that, anti-apoptotic mRNA might be highly or overexpressed whereas pro-apoptotic mRNA might be under-expressed or suppressed in human colorectal adenocarcinoma.

In cancer cells, induction of Bax initiates cell death. Bax overexpression increases apoptosis induced by chemotherapeutic agents (Kobayashi *et al.*, 2000).

Bax may induce apoptosis via pore-formation, BH3 domain. Bad can interact with anti-apoptotic genes of Bcl family and antagonizes their anti-apoptotic functions. Bad gene may have undergone some somatic mutation; Bad mutant had the ability to retain its pro-apoptotic function (Adachi and Imai, 2002).

COX-2, the inducible isoform, is regularly expressed at low levels in colonic mucosa. COX-2 may contribute to carcinogenesis and the malignant phenotype of tumor cells by inhibiting apoptosis, increasing angiogenesis, increasing invasiveness, modulating inflammation or immuno-suppression and conversion of procarcinogens to carcinogens (Dempke *et al.*, 2001). COX-2 expression is highly expressed (Kargman *et al.*, 1995; Eberhart *et al.*, 1994; Williams *et al.*, 1996) detected and in 80-90% of colorectal adenocarcinomas (Maihofner *et al.*, 2003). NF- κ B plays a crucial role in induction of COX-2 in various cell types (Mayo and Baldwin, 2000). In addition, NF- κ B has been shown to play an important role in development of cancer and metastasis (Yang *et al.*, 1999). It can antagonize p53 protein (Kher and Bacallao, 2001).

These anti- and pro-apoptotic mRNA may be expressed in low copy, which is not detectable. By using RT *in situ* PCR, it enhances sensitivity and thus enables localization of low abundance of mRNA in a cell. This method is also highly specific and enables the identification sites of RNA transcript production in tissues. By using formalin fixed, paraffin embedded, nucleus of a cell provides a relatively dense matrix of DNA, RNA and proteins, as they are extensively cross-linked to form a complex, 3-dimensional labyrinth. This method provides a higher surface to volume ratio (Nuovo, 1996). Protease digestion duration and DNase digestion is crucial to allow entrance of reagents and eliminate non-specific priming respectively.

In immunodetections, the non-radioactive digoxigenin-11-dUTP is end-labeled at the 3' end of the amplified mRNA. Digoxigenin is not found in mammalian cells. Anti-digoxigenin gold will bind to digoxigenin and can be detected by DAB chromogen, which is observed as brown staining.

CONCLUSION

Our findings conclude that COX-2, NF- κ B, Bax and Bad genes are expressed in human colorectal cancer and normal human colon in cytoplasm and/or nuclei of the cells. In comparing human normal and colorectal cancer, both anti-apoptotic genes are expressed at higher level compared to pro-apoptotic genes in colon adenocarcinoma tissue. Therefore, COX-2 and NF- κ B may contribute to the early stage of

development of colorectal adenocarcinoma or tumorigenesis. Bax and Bad genes are also expressed to induce apoptosis to the proliferating glandular cells.

ACKNOWLEDGEMENT

We are grateful to Nor Hasni Shamsudin (Pathologist, Ministry of Health Malaysia) for providing human colorectal adenocarcinoma samples. There is no conflict of interest that would prejudice the impartiality of this study.

REFERENCES

- Adachi, M. and K. Imai, 2002. The proapoptotic BH3-only protein BAD transduces cell death signals independently of its interaction with Bcl-2. *Cell Death Differ.*, 9: 1240-1247. DOI: 10.1038/sj.cdd.4401097
- Dempke, W., C. Rie, A. Grothey and H.J. Schmoll, 2001. Cyclooxygenase-2: A novel target for cancer chemotherapy? *J. Cancer Res. Clin. Oncol.*, 127: 411-417. DOI: 10.1007/S004320000225
- Eberhart, C.E., R.J. Coffey, A. Radhika, F.M. Giardiello and S. Ferrenbach *et al.*, 1994. Upregulation of cyclooxygenase-2 gene expression in human colorectal adenomas and adenocarcinomas. *Gastroenterology*, 107: 1183-1188. PMID: 7926468
- Fujimoto, K., H. Yasuda, Y. Sato and K. Yamamoto, 1995. A role for phosphorylation in the proteolytic processing of the human NF- κ B 1 precursor. *Gene*, 165: 183-189. DOI: 10.1016/0378-1119(95)00507-3
- Giovannucci, E., E.B. Rimm, M.J. Stampfer, G.A. Colditz and A. Ascherio *et al.*, 1994. Aspirin use and the risk for colorectal cancer in male health professionals. *Ann. Int. Med.*, 121: 241-246. <http://www.annals.org/content/121/4/241.abstract>
- Hanif, R., A. Pittus, Y. Fag, M.I. Koutsos and L. Qiao *et al.*, 1996. Effects of nonsteroidal anti-inflammatory drugs on proliferation and on induction of apoptosis in colon cancer cells by a prostaglandin-independent pathway. *Biochem. Pharmacol.*, 52: 237-245. DOI: 10.1016/0006-2952(96)00181-5
- Hasegawa, K., W. Ichikawa, T. Fujita, R. Ohno and T. Okusa *et al.*, 2001. Expression of Cyclooxygenase-2 (COX-2) mRNA in human colorectal adenomas. *Eur. J. Cancer*, 37: 1467-1474. [http://www.ejccancer.info/article/S0959-8049\(01\)00137-X/abstract](http://www.ejccancer.info/article/S0959-8049(01)00137-X/abstract)
- Ishibashi, Y., K. Nishimaki, S. Asoh, R. Nanbo-Wakao and T. Yamada *et al.*, 1998. Pore formation domain of human pro-apoptotic Bax induces mammalian apoptosis as well as bacterial death without antagonizing anti-apoptotic factors. *Biochem. Biophys. Res. Commun.*, 243: 609-616. DOI: 10.1006/bbrc.1998.8145
- Lee, J.W., Y.H. Soung, S.Y. Kim, S.W. Nam and C.J. Kim *et al.*, 2004. Inactivating mutations of proapoptotic Bad gene in human colon cancers. *Carcinogenesis*, 25: 1371-1376. DOI: 10.1093/carcin/bgh145
- Kargman, S.L., G.P. O'Neill, P.J. Vickers, J.F. Evans and J.A. Mancini *et al.*, 1995. Expression of prostaglandin G/H synthase-1 and -2 protein in human colon cancer. *Cancer Res.*, 55: 2556-2559. PMID: 7780968
- Kher, R. and R. Bacallao, 2001. Direct *in situ* reverse transcriptase-polymerase chain reaction. *Am. J. Physiol. Cell Physiol.*, 281: C726-C732. <http://ajpcell.physiology.org/cgi/content/full/281/2/C726>
- King, R.J.B. and M.W. Robins, 2006. *Cancer Biology*. 3rd Edn., Pearson/Prentice Hall, England, ISBN: 0131294547, pp: 292.
- Kobayashi, T., H. Sawa, J. Morikawa, W. Zhang and H. Shiku, 2000. Bax induction activate apoptotic cascade via mitochondria cytochrome c release and Bax of the expression enhances apoptosis induced by chemotherapeutic agents in DLD-1 colon cancer cells. *Jap. J. Cancer Res.*, 91: 1264-1268. DOI: 10.1111/j.1349-7006.2000.tb00913.x
- Lim, G.C.C., 2006. Clinical oncology in Malaysia: 1914 to present. *Biomed. Imag. Interv. J.*, 2: e18-e18. DOI: 10.2349/bijj.2.1.e18
- Maihofner, C., M.P. Charalambous, U. Bhambra, T. Lightfoot and G. Geisslinger *et al.*, 2003. Expression of cyclooxygenase-2 parallels expression of interleukin-1 beta, interleukin-6 and NF-kappaB in human colorectal cancer. *Carcinogenesis*, 24: 665-671. DOI: 10.1093/carcin/bgg006
- Mayo, M.W. and A.S. Baldwin, 2000. The transcription factor NF- κ B: Control of oncogenesis and cancer therapy resistance. *Biochim. Biophys. Acta*, 1470: M55-M62. DOI: 10.1016/S0304-419X(00)00002-0
- Midgley, R. and D. Kerr, 1999. Colorectal cancer. *Lancet*, 353: 391-399. PMID: 9950460
- Nuovo, G.J., 1996. The foundation of successful RT *in situ* PCR. *Front. Biosci.*, 1: c4-c15. <http://www.bioscience.org/1996/v1/c/nuovo1/html/nuovo.pdf>

- Rainford, L., 2000. Health in England 1998: Investigating the Links Between Social Inequalities and Health-A Survey of Adults Aged 16 and Over in England: Investigating the Links Between Social Inequalities and Health a Survey of Adults Aged 16 and Over in England Carried Out by the Social Survey Division of ONS on Behalf of the Health Education Authority. 3rd Edn., Stationery Office, London, ISBN: 0116213574, pp: 303.
- Robbins, S.L., 2004. The Oral Cavity and Gastrointestinal Tract. In: Robbins and Cotran Pathologic Basis of Disease, Kumar, V., N. Fausto and A. Abbas (Eds.). Saunders, Philadelphia, ISBN: 10: 0721601871, pp: 582-584.
- Ruegg, C., O. Dormond and A. Mariotti, 2004. Endothelial cell integrins and COX-2: Mediators and therapeutic of tumor angiogenesis. *Biochimica Biophysica Acta (BBA)-Rev. Cancer*, 1654: 51-67. DOI: 10.1016/j.bbcan.2003.09.003
- Samojednya, M.P., D. Kokochinskab, A. Samojednya, U. Mazureka and R. Partykab *et al.*, 2004. Expression of cell survival/death genes: Bcl-2 and Bax at the rate of colon cancer prognosis. *Biochimica Biophysica Acta*, 1741: 25-29. DOI: 10.1016/j.bbadis2004.11.021
- Tsuji, M., S. Kawano and R.N. DuBois, 1997. Cyclooxygenase-2 expression in human colon cancer cells increases metastatic potential. *Proc. Natl. Acad. Sci. USA.*, 94: 3336-3340. <http://www.jstor.org/stable/41824>
- Wiesner, G.L., D. Daley, S. Lewis, C. Ticknor and P. Platzer *et al.*, 2003. A subset of familial colorectal neoplasia kindreds linked to chromosome 9q22.2-31.2. *PNAS*, 100: 12961-12965. DOI: 10.1073/pnas.2132286100
- Williams, C.S., C. Luongo, A. Radhika, T. Zhang and L.W. Lamps *et al.*, 1996. Elevated cyclooxygenase-2 levels in min mouse adenomas. *Gastroenterology*, 111: 1134-1140. [http://www.gastrojournal.org/article/S0016-5085\(96\)70083-5/abstract](http://www.gastrojournal.org/article/S0016-5085(96)70083-5/abstract)
- Williams, C.S., W. Smalley and R.N. Dubois, 1997. Aspirin use and potential mechanisms for colorectal cancer prevention. *J. Clin. Invest.*, 100: 1325-1329. DOI: 10.1172/JCI 119651
- Yang, J.P., M. Hori, N. Takahashi, T. Kawabe, H. Kato *et al.*, 1999. NF- κ B subunit p65 binds to 53BP2 and inhibits cell death induced by 53BP2. *Oncogene*, 18: 5177-5186. <http://www.nature.com/onc/journal/v18/n37/full/1202904a.html>